

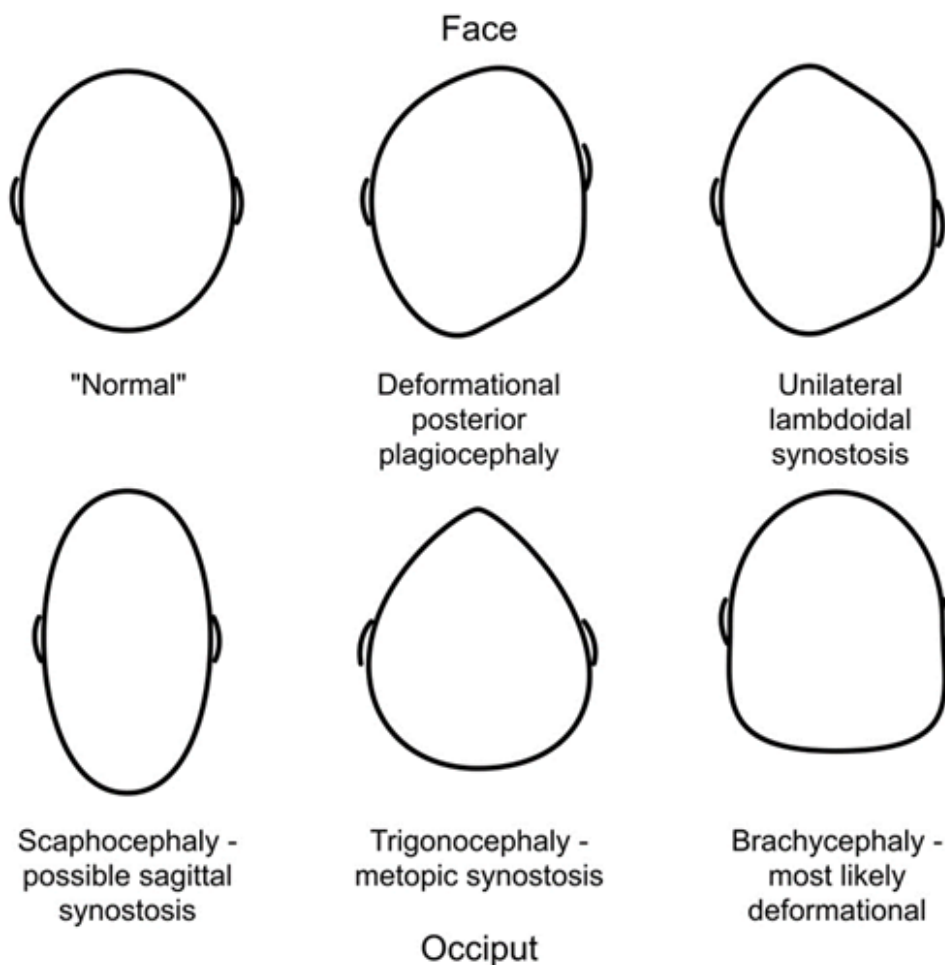
Infant head shape abnormalities

Overview

- Head shape abnormalities are common - present in **25%** of infants aged under 6 months
- Deformational posterior **plagiocephaly** accounts for the vast majority of cases
- **Craniosynostosis** (early fusion of cranial sutures) is **rare**
- Clinical examination alone is sufficient to differentiate between deformational plagiocephaly and craniosynostosis in 95% of cases, imaging may be required in the remainder
- Deformational plagiocephaly resolves spontaneously, but may take 2-3 years for complete resolution

Clinical approach

- Measure and plot orbitofrontal circumference (OFC)
- Assess overall muscle tone
- Observe the head from above:



Infant head shape abnormalities

- **Asymmetrical occipital flattening** (the most common reason for seeking advice)
 - ◇ In deformational posterior plagiocephaly, the head will appear flattened to one side of the occiput and the ear on the ipsilateral side will appear to be displaced **anteriorly** compared to the contralateral ear. If there is accompanying anterior asymmetry, the forehead will be prominent on the **ipsilateral side**
 - ◇ In unilateral lambdoidal craniosynostosis, the ear on the ipsilateral side will appear to be displaced posteriorly compared with the contralateral ear. If there is accompanying anterior asymmetry, the forehead will be prominent on the contralateral side. In addition, when viewed from the back of the head, the ear on the flattened side will appear to be displaced inferiorly.
- **Ridging of sutures**
 - ◇ Ridging most commonly occurs in the metopic suture. In the absence of an abnormal head shape (typically a reduction in bitemporal diameter resulting in trigonocephaly)
 - ◇ Ridging may also be seen in the sagittal suture; this is indicative of sagittal craniosynostosis and occurs as a result of peri-sutural osteosclerosis and is detectable from very early infancy
 - ◇ Ridging may sometimes be mistaken for overlapping sutures. This may occur as a result of cranial moulding during delivery and will resolve in first days of life or as a result of microcephaly – measurement of OFC will identify this.
- Examine for torticollis, which may contribute to deformational plagiocephaly

Management

- Suspected craniosynostosis should be referred to a general paediatric clinic for confirmation and subsequent referral to a supraregional craniofacial unit
- Active repositioning for plagiocephaly should be explained – wait until the child is asleep and then reposition the head
- Helmets are not available on the NHS – it is likely that they improve appearances more quickly than active repositioning alone but the final cosmetic results are likely to be equal
- Children with torticollis should be referred for physiotherapy

Red flags

- OFC crossing through centiles – refer to general paediatrics
- Poor muscle tone – plagiocephaly may be the first sign of neurodevelopmental problems – refer for further assessment to general or community paediatrics

Patient information: <http://www.nhs.uk/Conditions/plagiocephaly/>